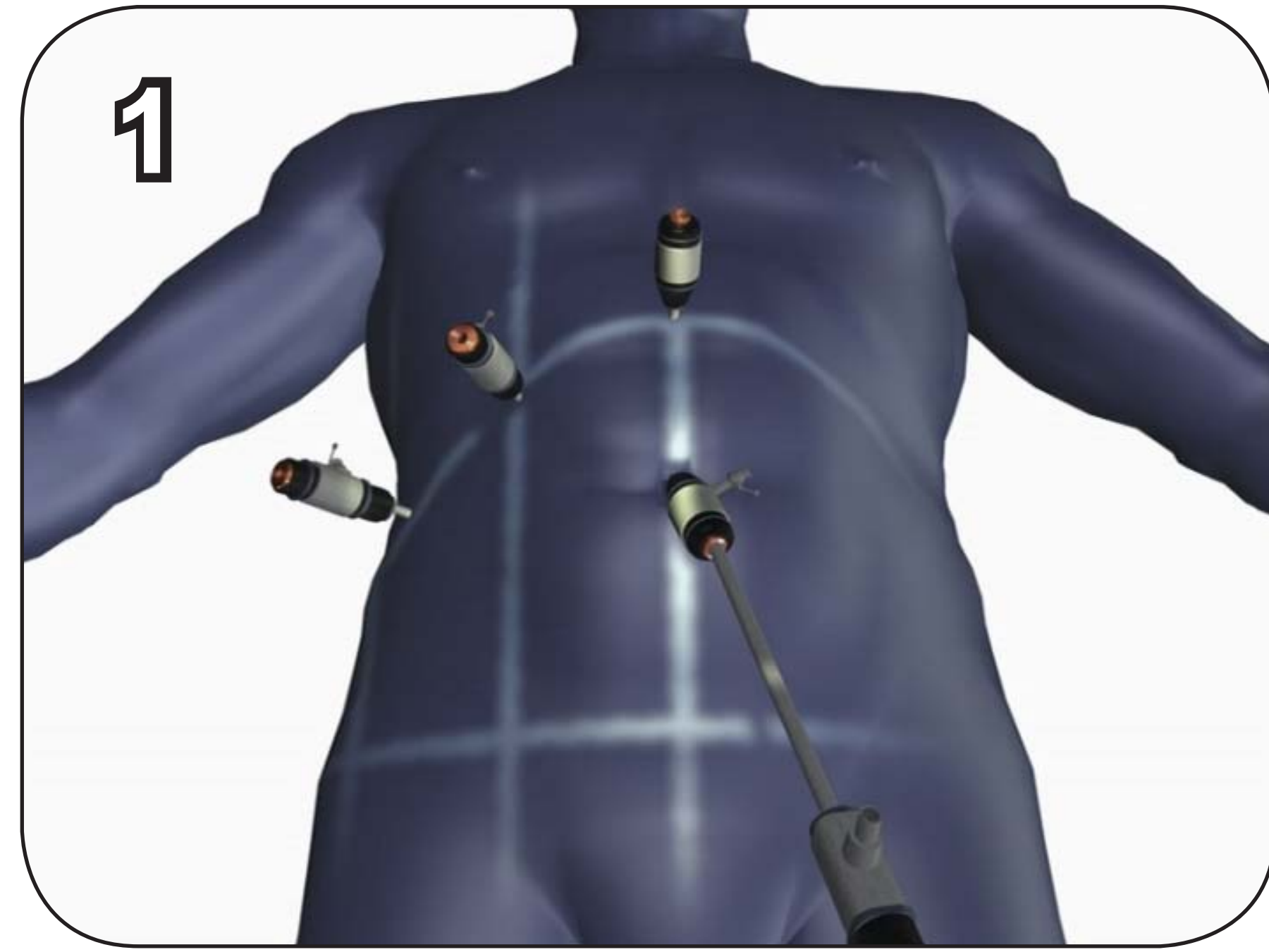




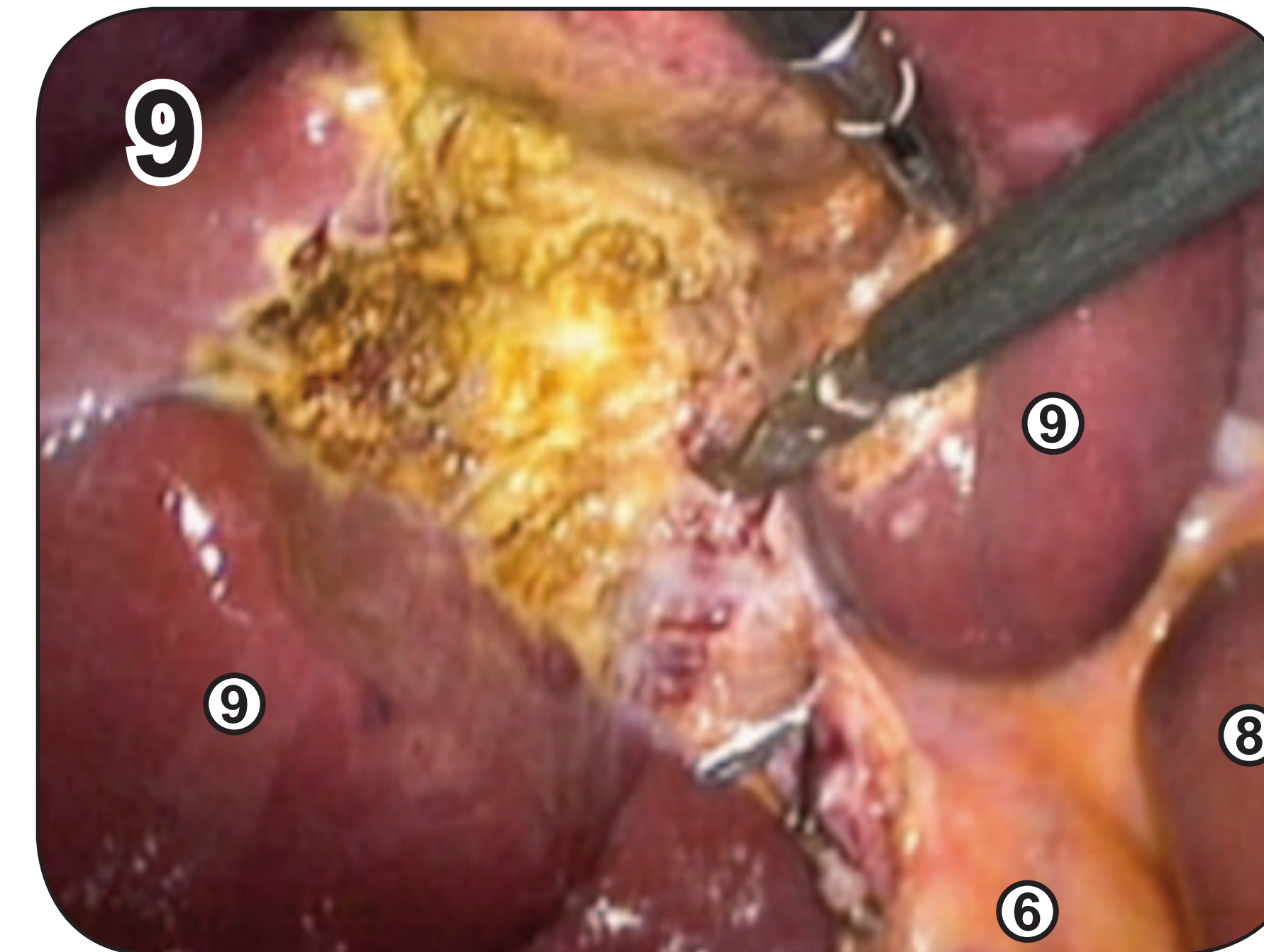
Laparoskopische Cholezystektomie

J. Kreuzer¹, P. Storz¹, P. Nedela¹, P. Wilhelm¹, T. Gehring¹, T. Giering¹, W. Kunert¹, A. Kirschniak¹

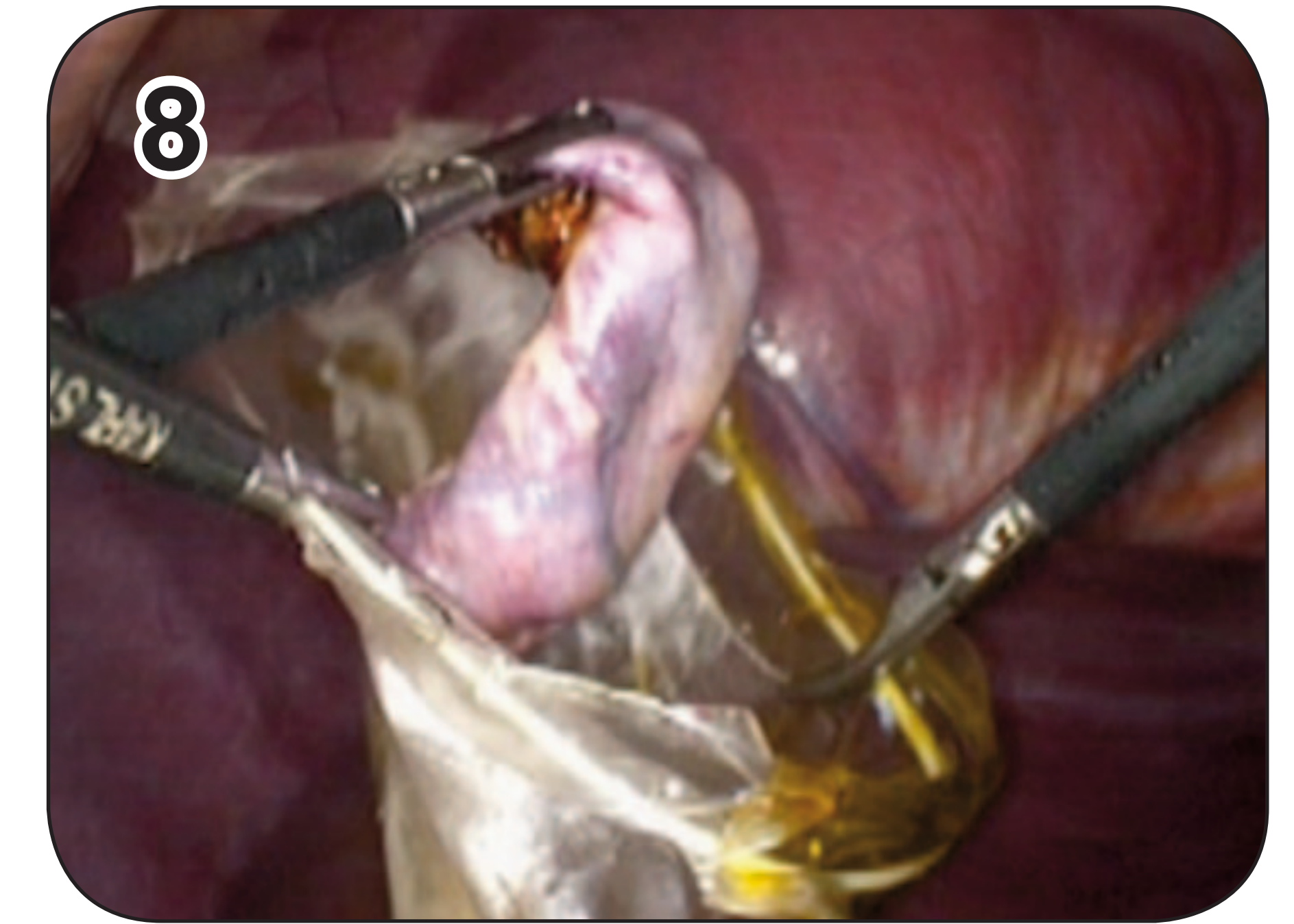(1) Arbeitsgruppe Experimentelle Minimal Invasive Chirurgie und Training -
Universitätsklinik für Allgemeine, Viszeral- und Transplantationschirurgie



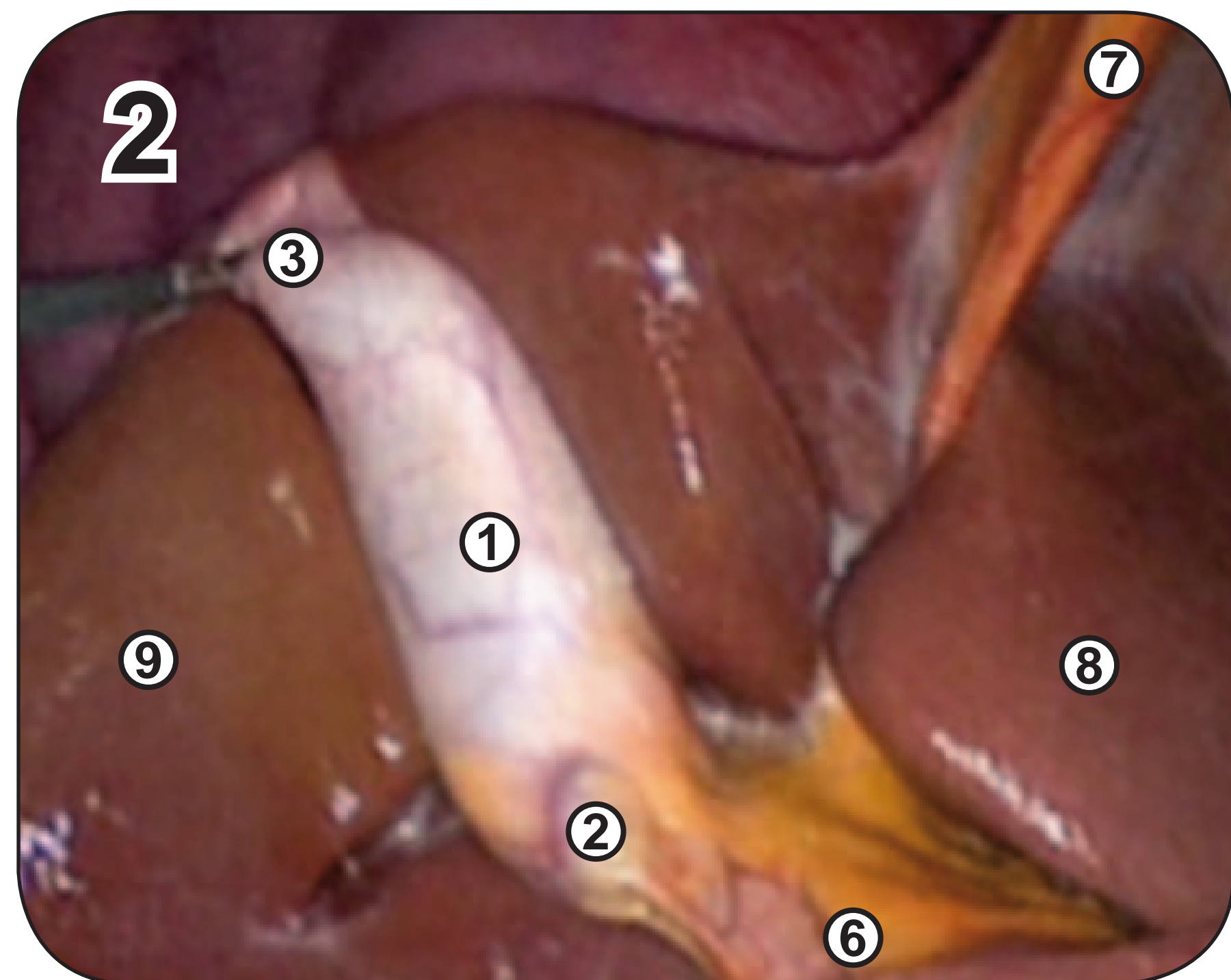
Trokarposition



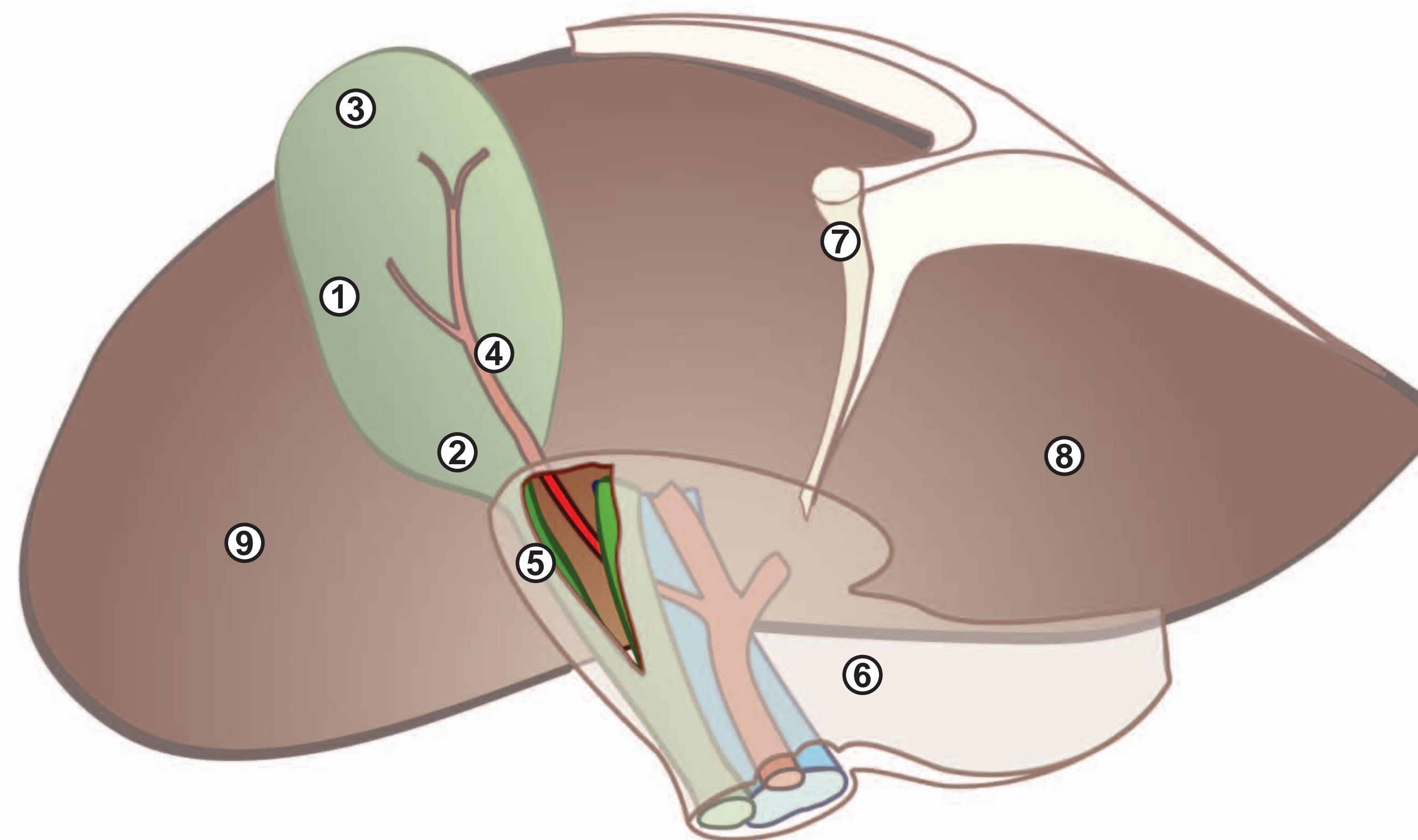
Blutstillung



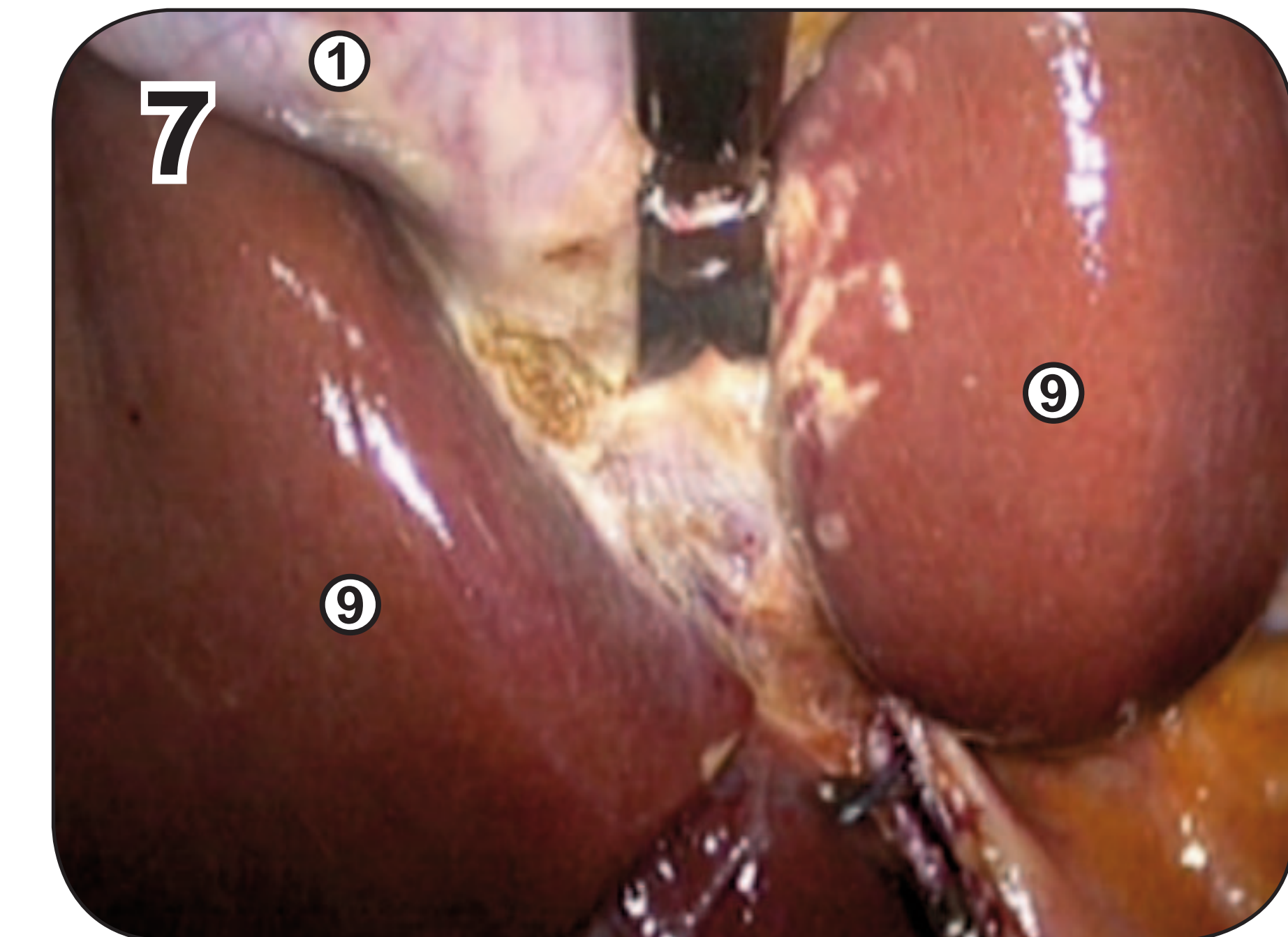
Bergung



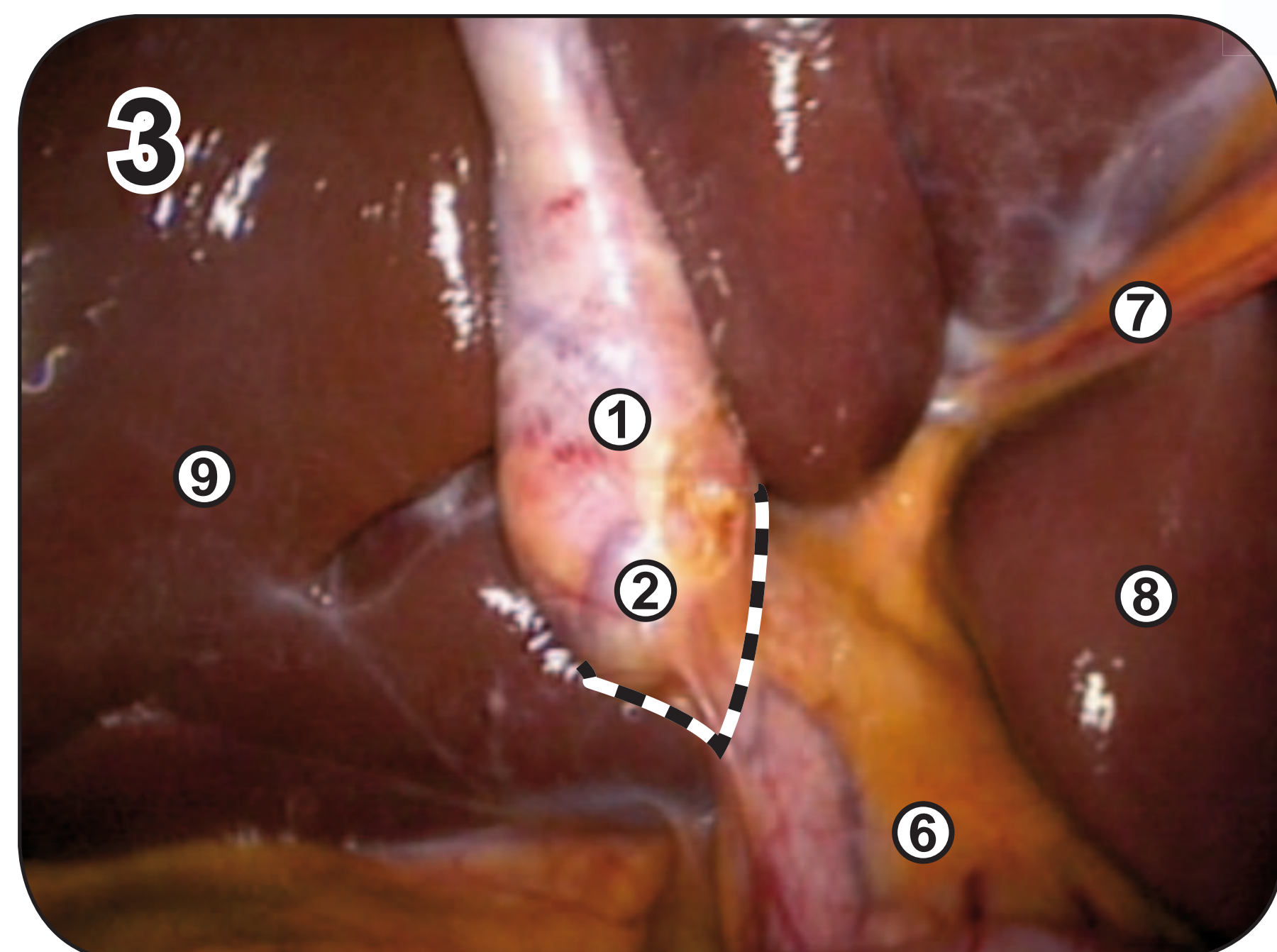
Retraktion der Leber
(Fasszange Assistent)



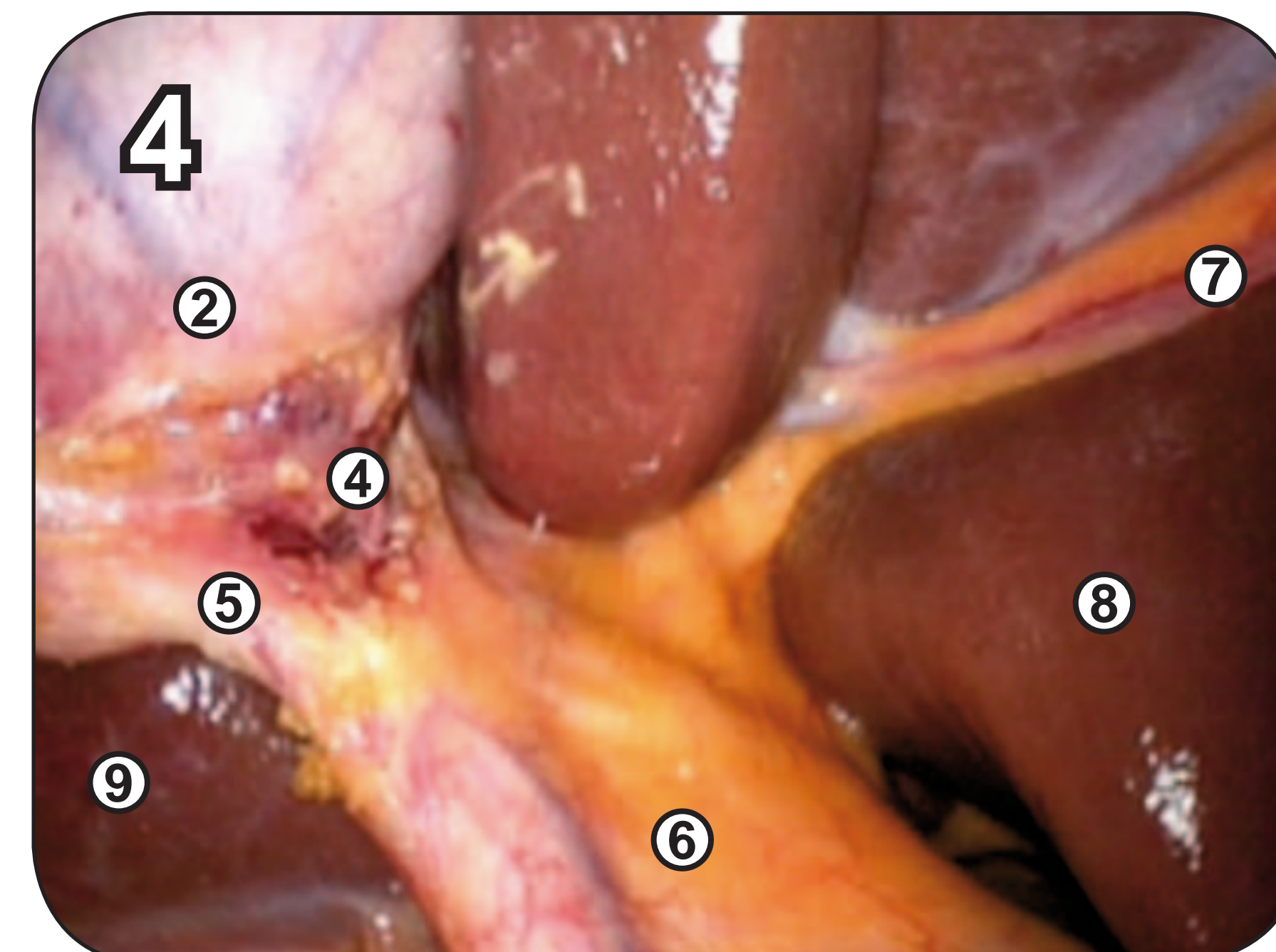
- ① Gallenblase
- ② Infundibulum
- ③ Fundus
- ④ A. cystica
- ⑤ D. cysticus
- ⑥ Lig. hepatoduodenale
- ⑦ Lig. teres hepatis
- ⑧ linker Leberlappen
- ⑨ rechter Leberlappen



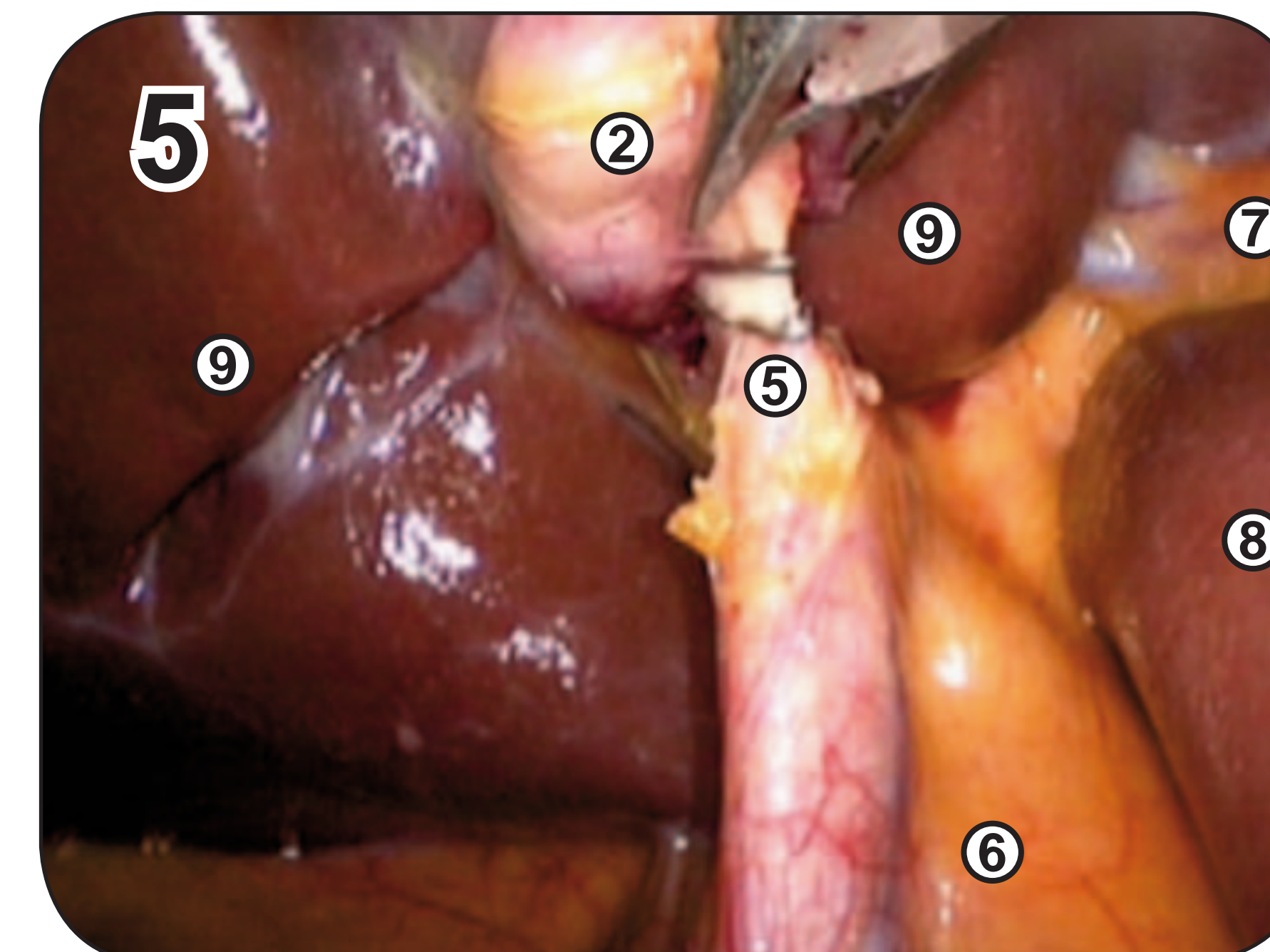
Herauslösen



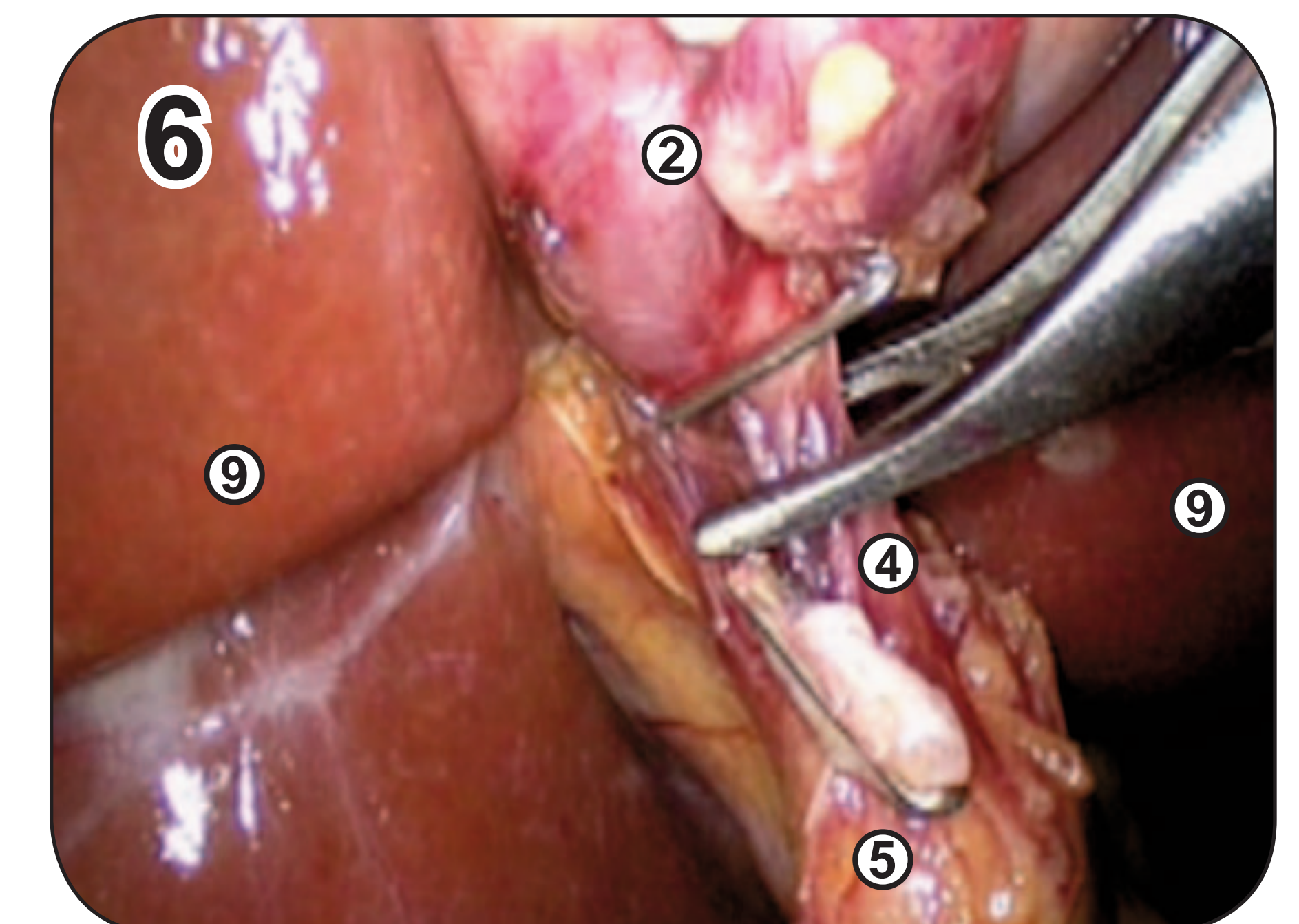
V-Präparation



Critical view



Clippen und Durchtrennen
des Ductus cysticus



Clippen und Durchtrennen
der Arteria cystica